

Epithelial tissue

Lec.2

Histology

Epithelia Characterizations

- 1- Epithelia are tissues consisting of closely apposed [highly packed] cells.**
- 2- With a narrow intercellular spaces and little amount of extracellular substances.**
- 3- Epithelia are **avascular** (Perfusion)**
- 4- All epithelia "grow" on an underlying layer of vascular connective tissue. The connective tissue and the epithelium are separated by a **basement membrane**.**
- 5. Epithelium **covers** all free surfaces of the body and **lines** the organs & large internal body cavities.**
- 6- Epithelium originate from the three embryonic germ layers [**Ectoderm, Endoderm and mesoderm**].**

7- Function Protection, Adsorption and in some Secretion if the epithelium was glandular epithelium.

- **Protecting underlying structures; e.g., epithelium lining the mouth.**
- **Acting as barriers; e.g., skin.**
- **Permitting the passage of substances; e.g., cells lining air sacs in lungs and nephrons in kidney.**
- **Secreting substances; e.g., pancreatic cells.**
- **Absorbing substances; e.g., lining of stomach and small intestine.**

Classification

➤ **Epithelium is classified to Membrane and glandular depending on the function.**

A\ Membrane Epithelium

- ❖ **Epithelia are classified on the basis of the **number** of cell layers and the **shape** of the cells in the surface layer.**
- ❖ **If there is only **one** layer of cells in the epithelium, it is designated **simple**. If there are **two** or more layers of cells, it is termed **stratified**.**
- ❖ **Cells in the surface layer are, as a rule, described according to their height as **squamous** (scale- or plate-like), **cuboidal** or **columnar**.**

A\ Membrane Epithelium

□ Number of layers of cells

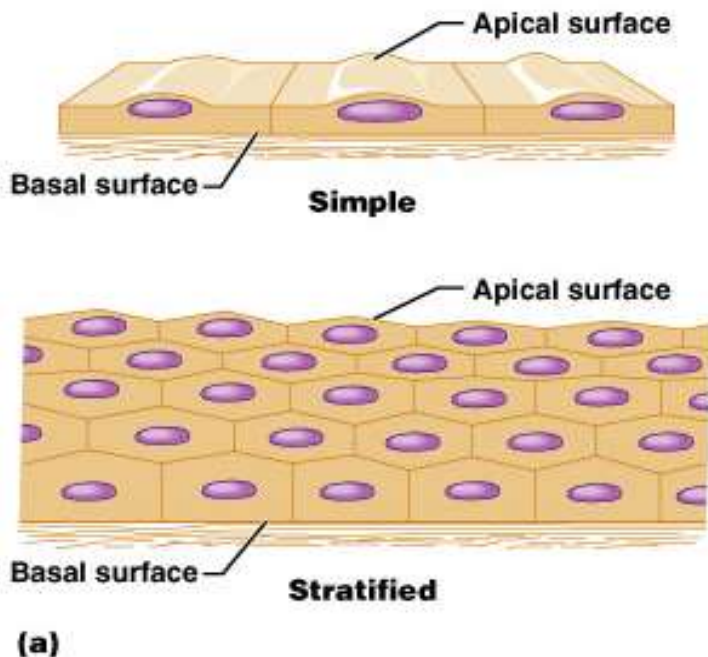
- **Simple-** one layer of cells. Each extends from basement membrane to the free surface
- **Stratified-** more than one layer.
- **Pseudostratified-** tissue appears to be stratified, but all cells contact basement membrane so it is in fact simple

□ Shape of cells

- **Squamous-** flat, scale-like
- **Cuboidal-** about equal in height and width
- **Columnar-** taller than wide

A\ Membrane Epithelium

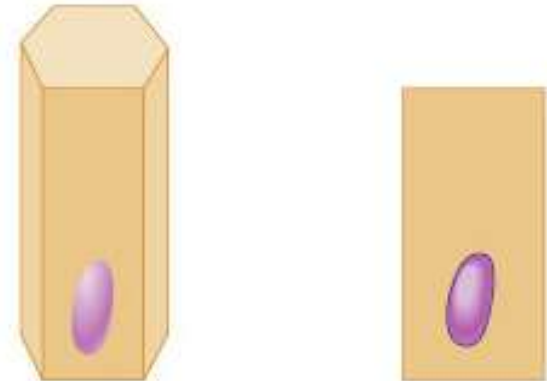
- Viewed from the surface of the epithelium they look rather like small polygons



Squamous



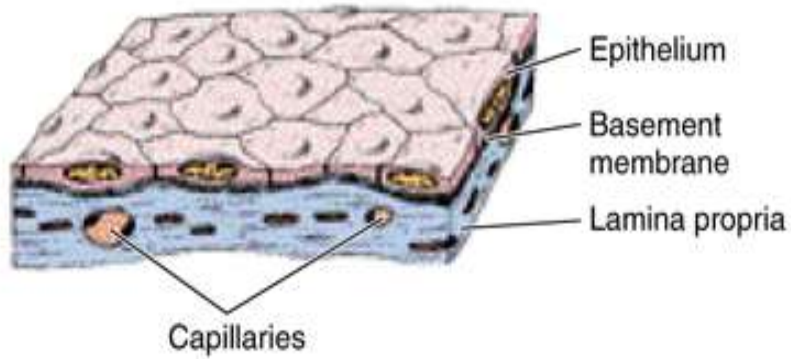
Cuboidal



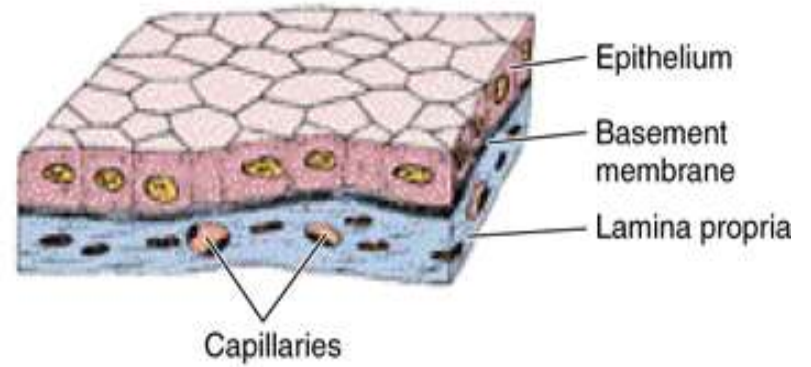
Columnar

(b)

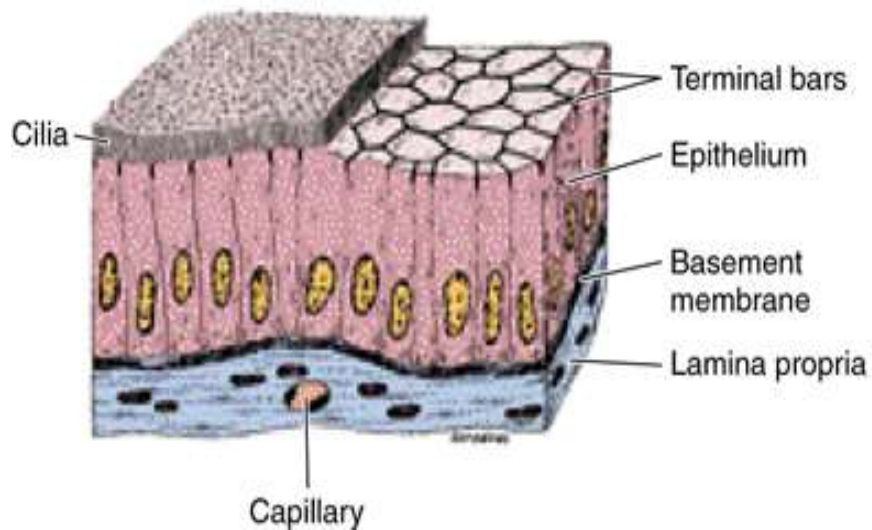
A Simple squamous epithelium



B Simple cuboidal epithelium



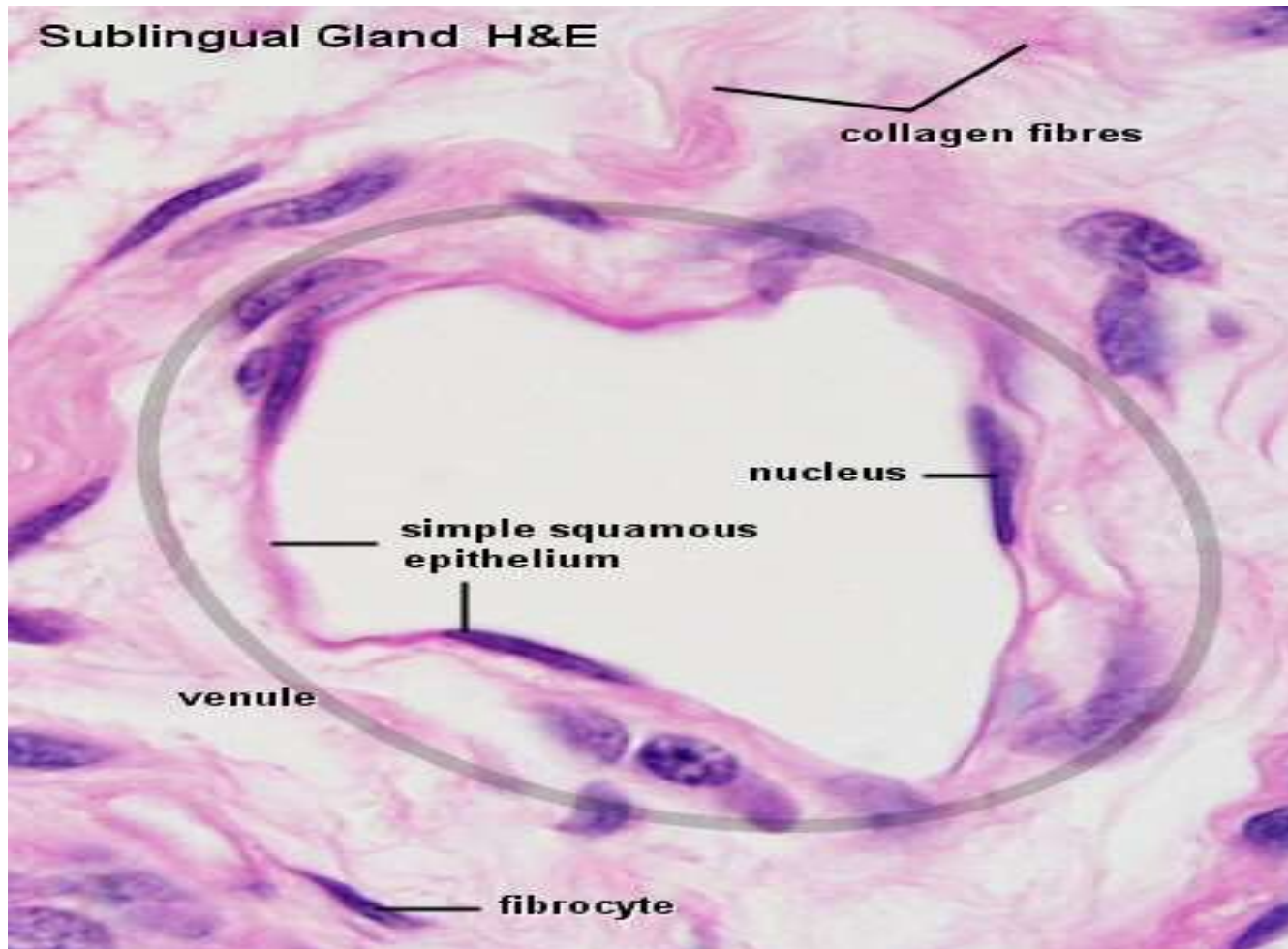
C Simple ciliated columnar epithelium



1- Simple Epithelia

Simple squamous epithelium

- This type is composed of a single layer of **flattened, scale- or plate-like cells**. It is quite common in the body.
- The nuclei of the epithelial cells are often flattened or ovoid, i.e. egg-shaped, and they are located close to the center of the cells.
- The large body cavities and heart, blood vessels and lymph vessels are typically lined by a simple squamous epithelium (**Termed mesothelium**) in body cavities, furthermore, the internal surfaces of blood and lymph vessels are lined by epithelium, here called (**endothelium**)
 - both are originated from the mesoderm.



Capillaries and other small vessels a "good" simple squamous epithelium (endothelium).

Free surface

Epithelial cells with little extracellular materials between the cells

Free surface

Nucleus

Surface view

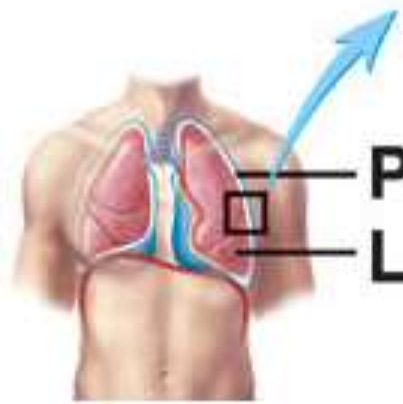
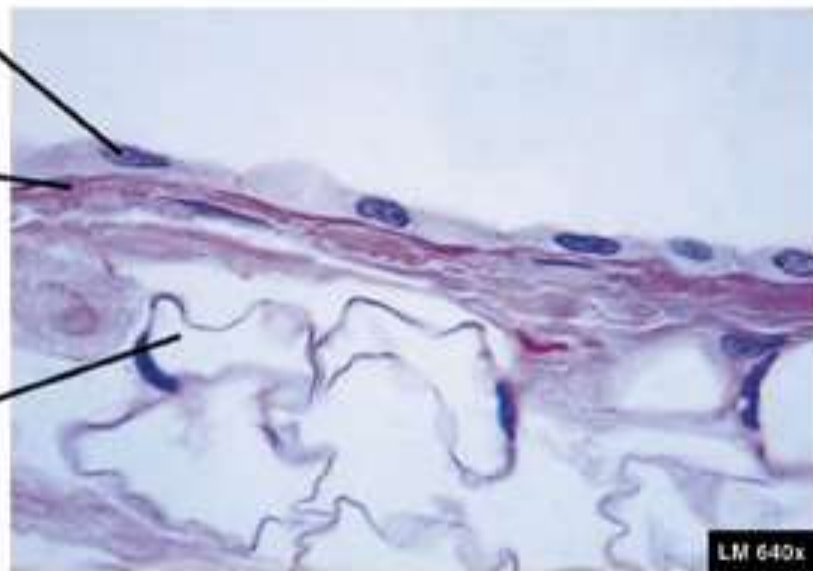
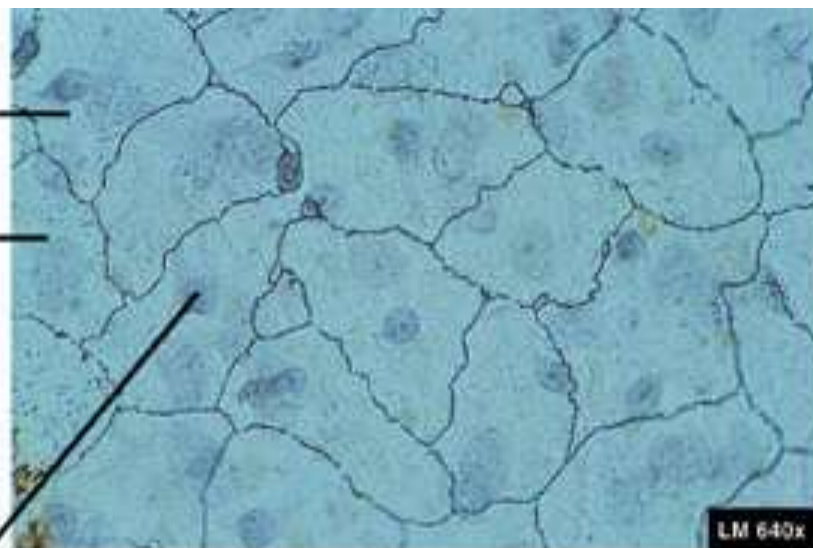
Basement membrane

Capillary

Pleura

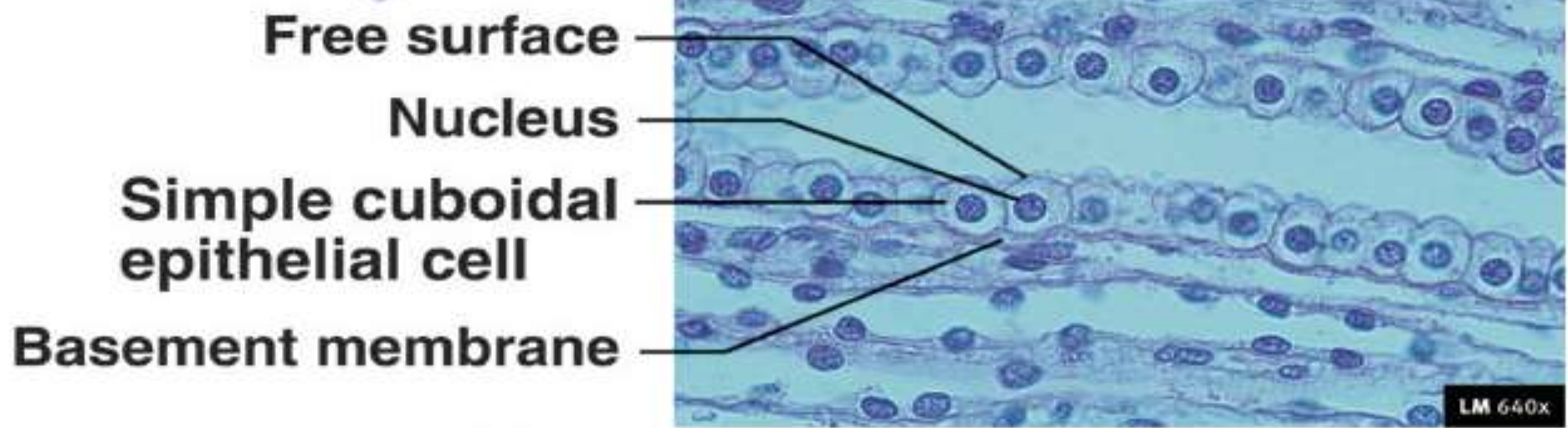
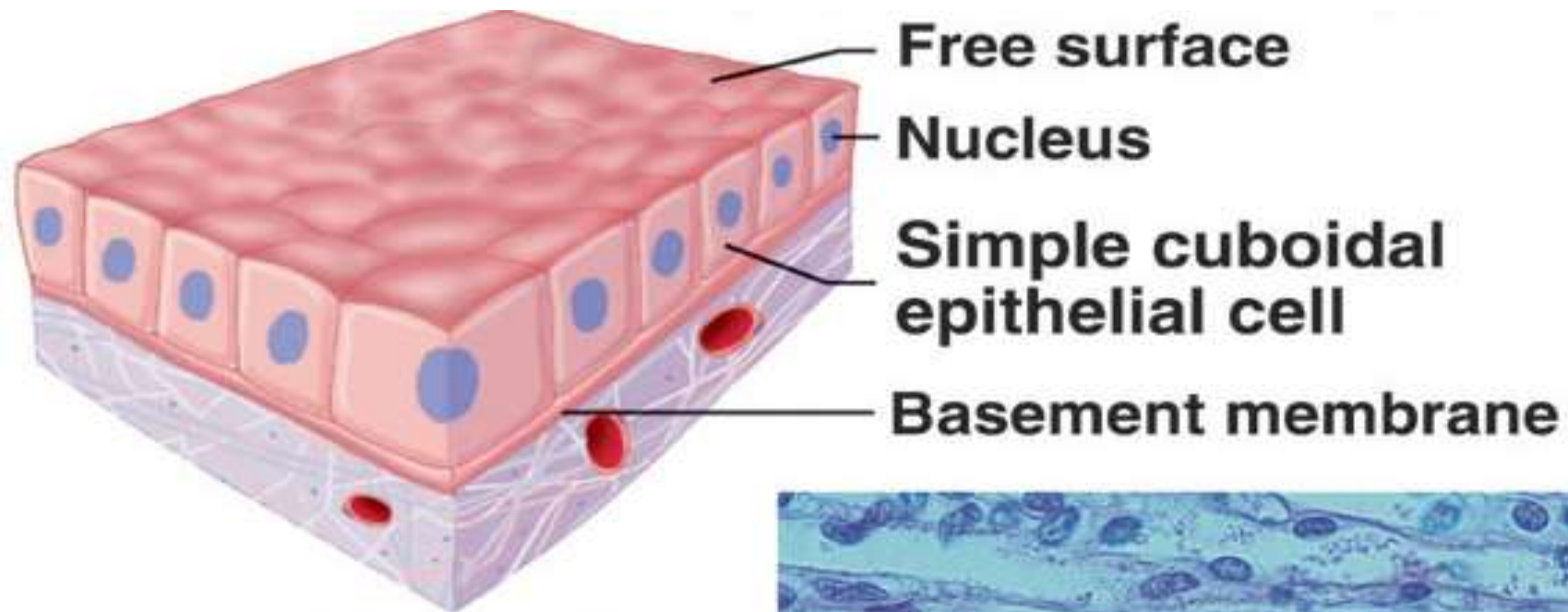
Lung

Cross-sectional view

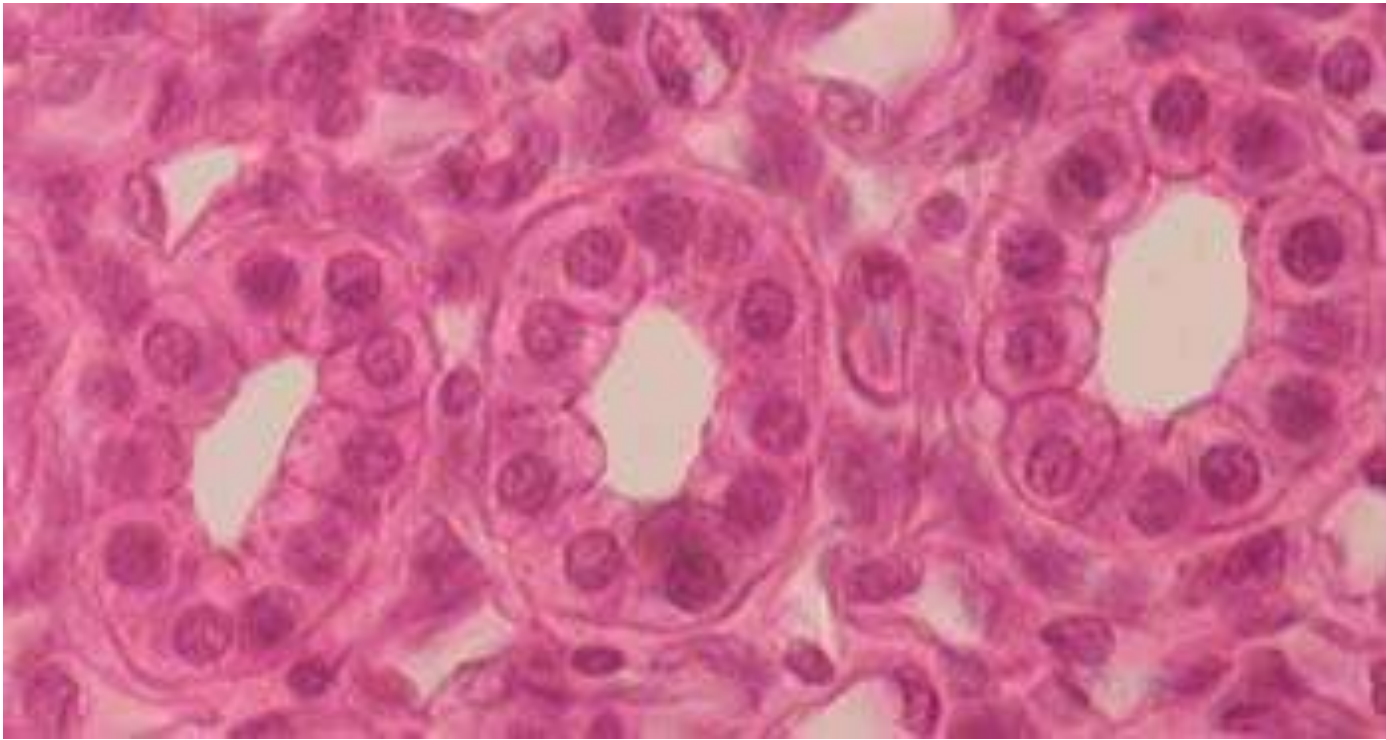


Simple cuboidal epithelium

- **Cells appear cuboidal in sections perpendicular to the surface of the epithelium.**
- **Viewed from the surface of the epithelium they look rather like small polygons.**
- **Simple cuboidal epithelium occurs in small excretory ducts [tubules] of many glands, the follicles of the thyroid gland, the tubules of the kidney and on the surface of the ovaries.**
- **Can there be "low cuboidal" epithelia?**



(b) Simple cuboidal epithelium
Kidney tubules, glands, lining of terminal bronchioles, etc.

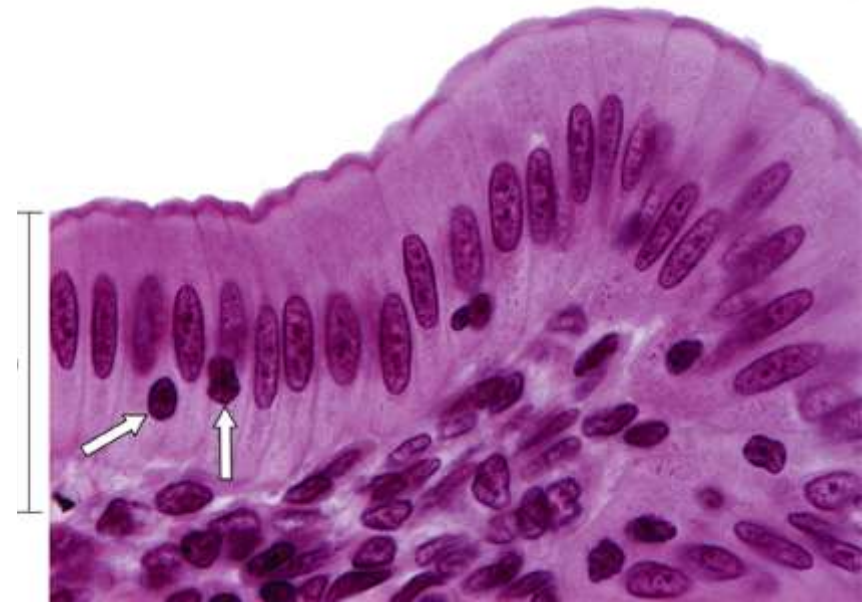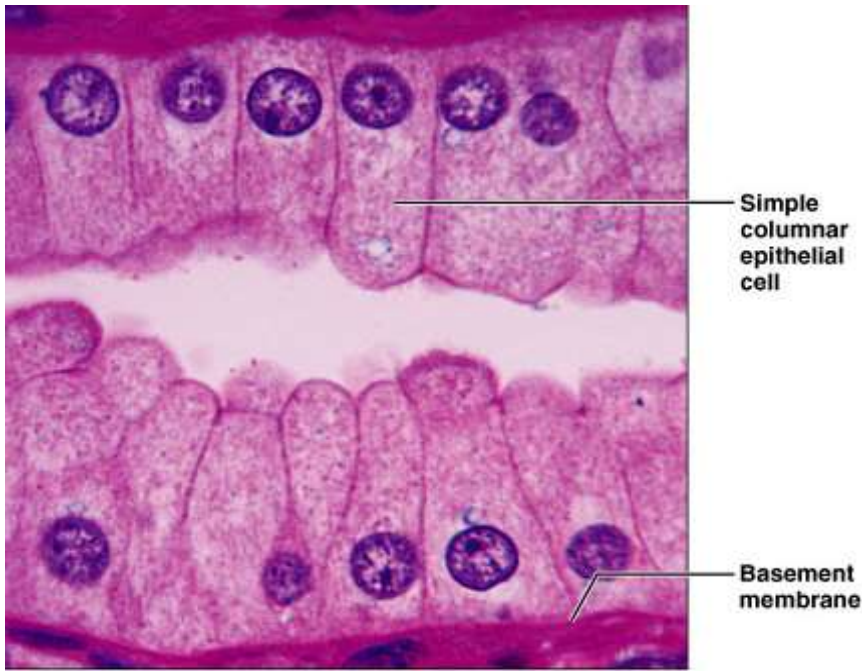


SIMPLE CUBOIDAL EPITHELIUM (Kidney Tubules)

Stained with haematoxylin and eosin

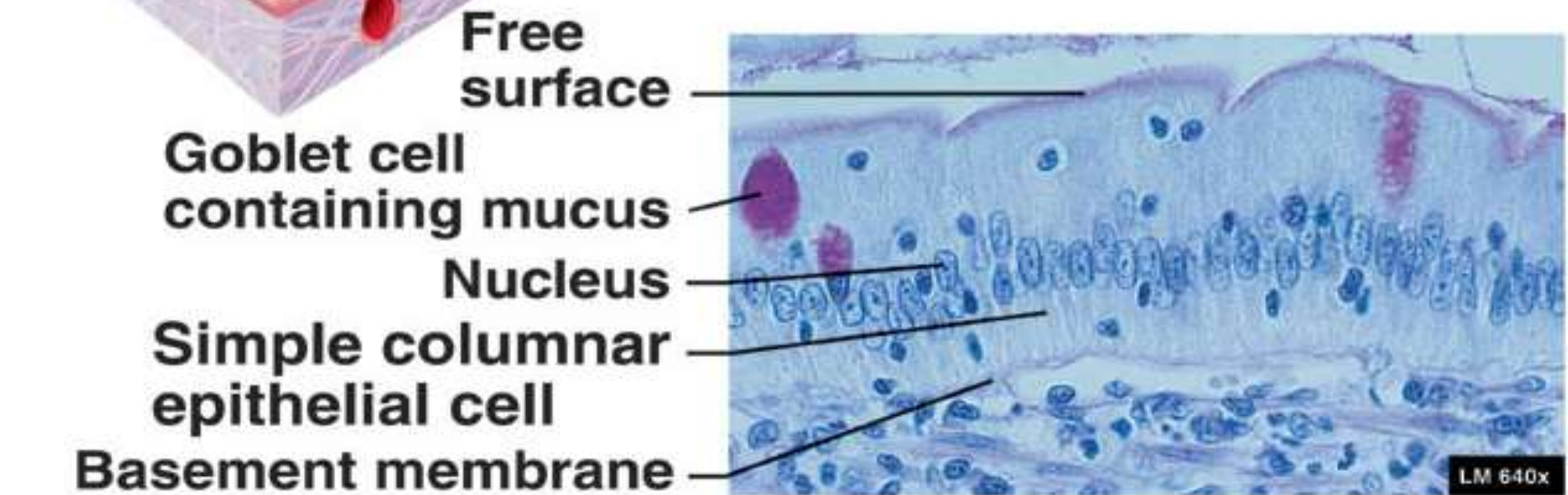
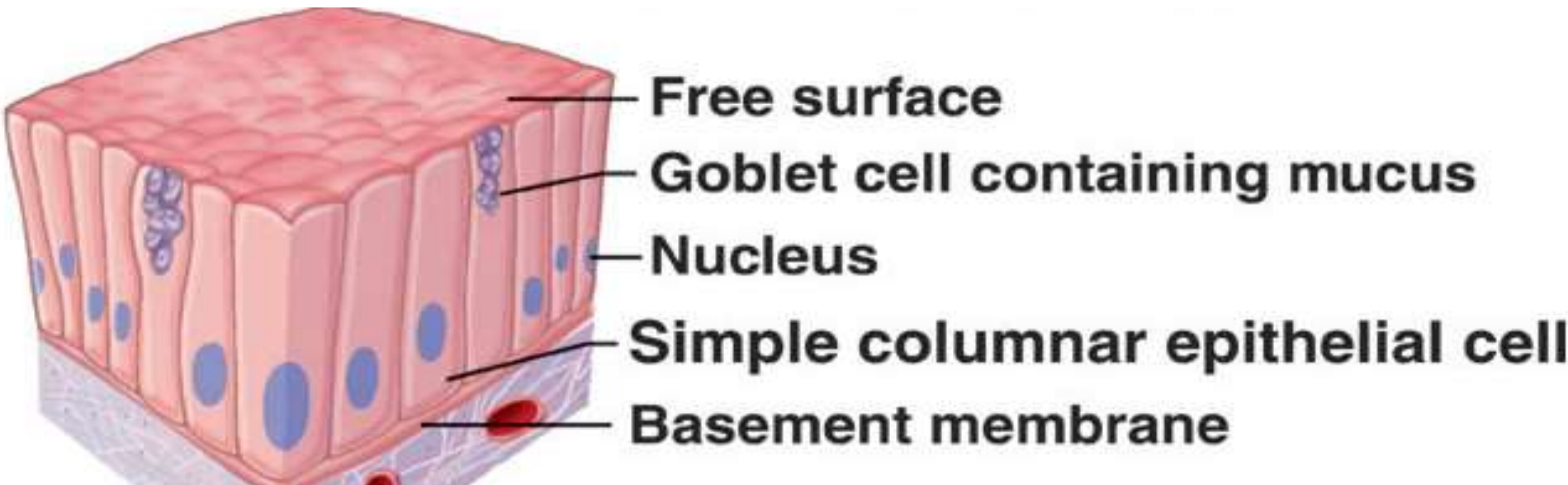
Simple columnar epithelium

- **The cells forming a simple columnar epithelium are **taller** than they are **wide**.**
- **The nuclei of cells within the epithelium are usually located at the **same height** within the cells - often close to the base of the cells.**
- **An example is the simple columnar epithelium which lines the internal surface of the gastrointestinal tract (GIT) from the cardiac of the stomach to the rectum.**



SIMPLE COLUMNAL EPITHELIUM

Glands, bronchioles, stomach, intestines, bile ducts, etc.

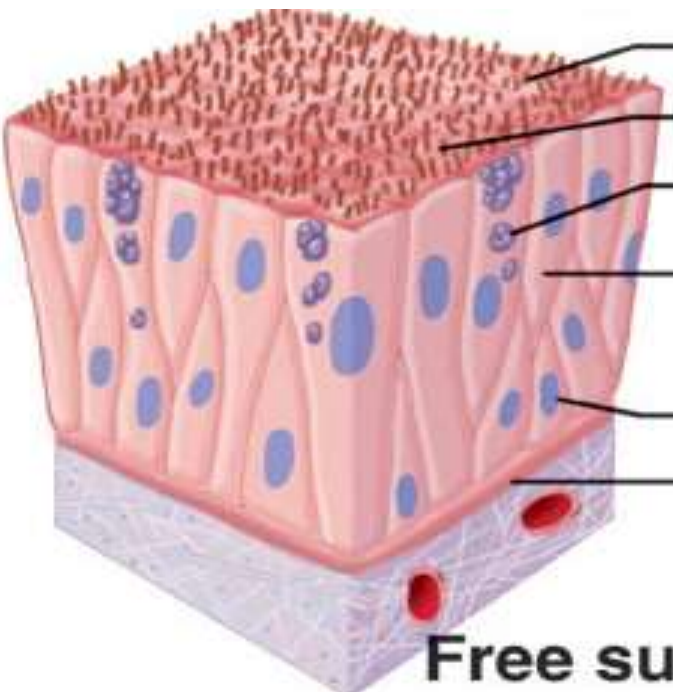


(c) Simple columnar epithelium

Glands, bronchioles, stomach, intestines, bile ducts, etc. 16

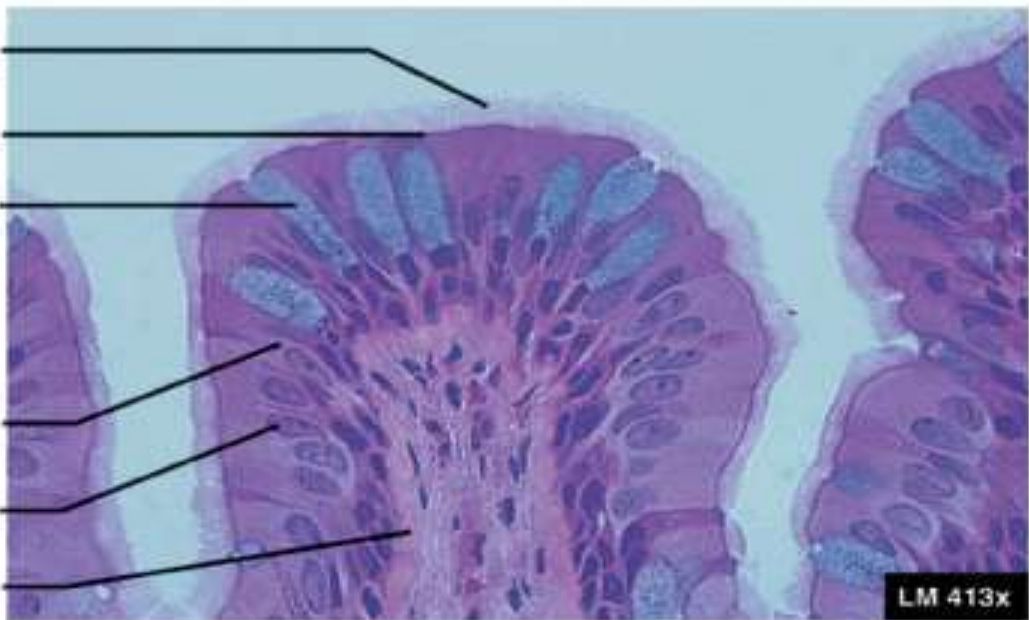
Pseudostratified columnar epithelium

- **All cells of this type of epithelium are in contact with the basement membrane, but **not all of them** reach the surface of the epithelium.**
- **Nuclei of the epithelial cells are typically located in the widest part of the cell. Consequently, the nuclei of cells which do or do not reach the surface of the epithelium are often located at different heights within the epithelium and give the epithelium a stratified appearance.**
- **The epithelium will look stratified but it is not – hence its name "Pseudostratified". Pseudostratified columnar epithelia are found in the excretory ducts of many glands.**
- **They are modified from simple columnar epithelium**
Pseudostratified columnar epithelium of the trachea is of the ciliated type.



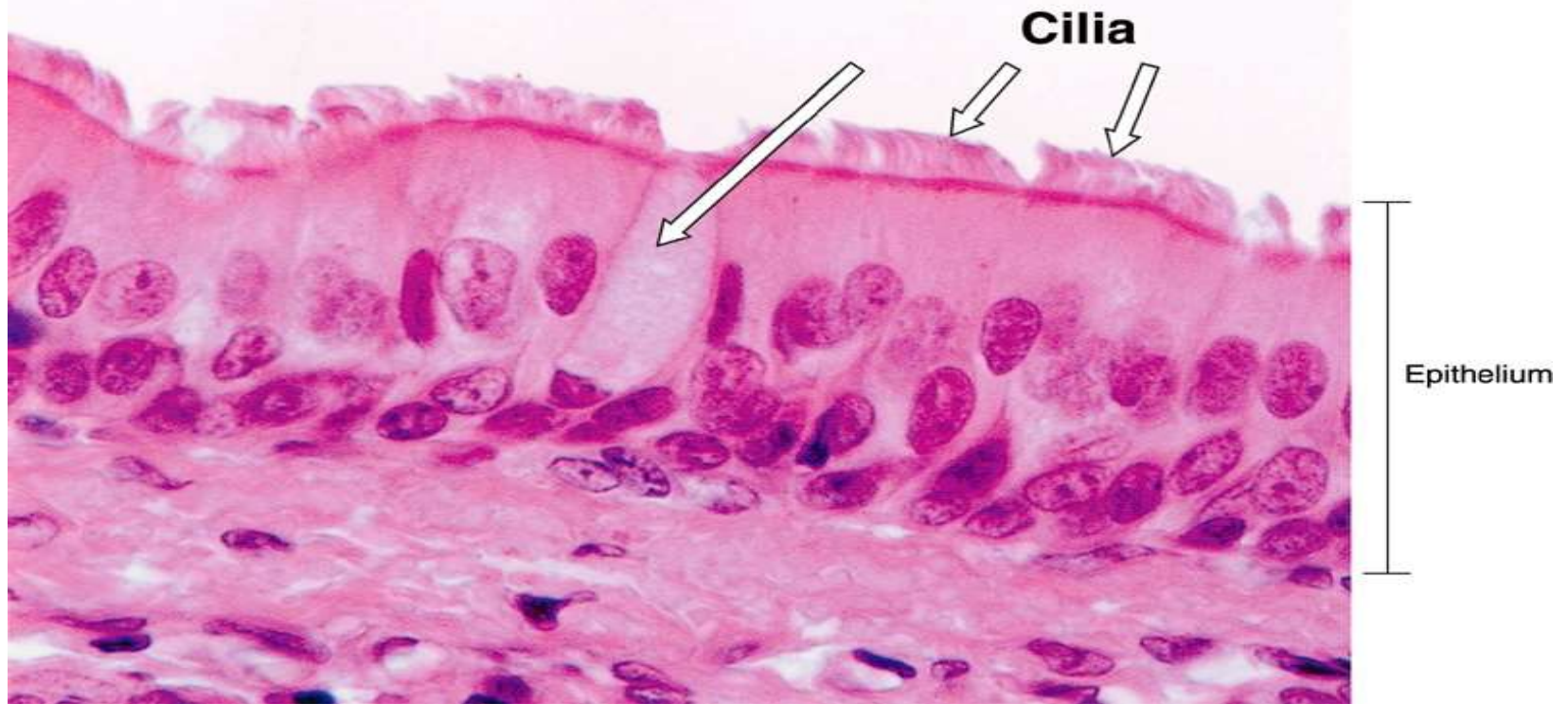Cilia
Free surface
Goblet cell containing mucus
Pseudostratified columnar epithelial cell
Nucleus
Basement membrane

Free surface
Goblet cell containing mucus
Pseudostratified columnar epithelial cell
Nucleus
Basement membrane



(g) Pseudostratified columnar epithelium

Lines nasal cavity & sinuses, auditory tubes, trachea, bronchi



Pseudostratified columnar epithelium of the trachea, formed by long and short cells. As some cells do not reach the surface of the epithelium their nuclei are present in different heights of the epithelial layer. Mucus-secreting cells, called goblet cells (arrow), intermingle with ciliated lining cells. (PA S)

2- Stratified Epithelia

- Contain two or more layers of cells.**
- Regenerate from below.**
- Major role is protection.**
- Are named according to the shape of cells at **apical layer**.**

❑ **Stratified Squamous Epithelium**

- **Specific types**

- **Non-keratinized – forms moist lining of body openings.**

- **Location**

- forms lining of esophagus, mouth, and vagina**

- **Keratinized – contain the protective protein keratin**

- **Surface cells are dead and full of keratin**

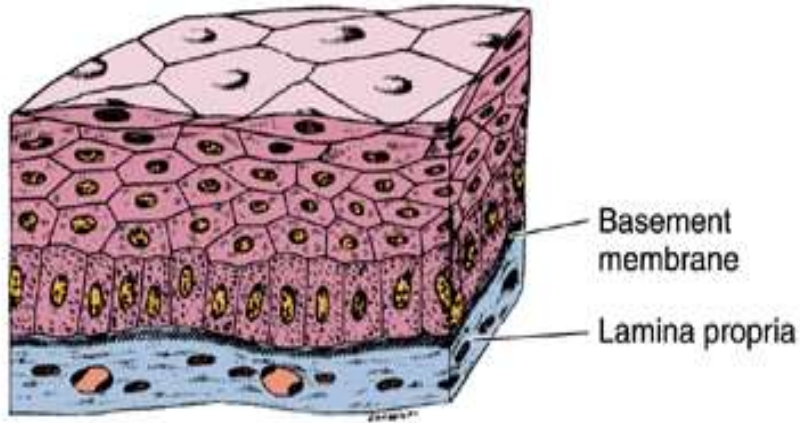
- **Location**

- forms epidermis of the skin**

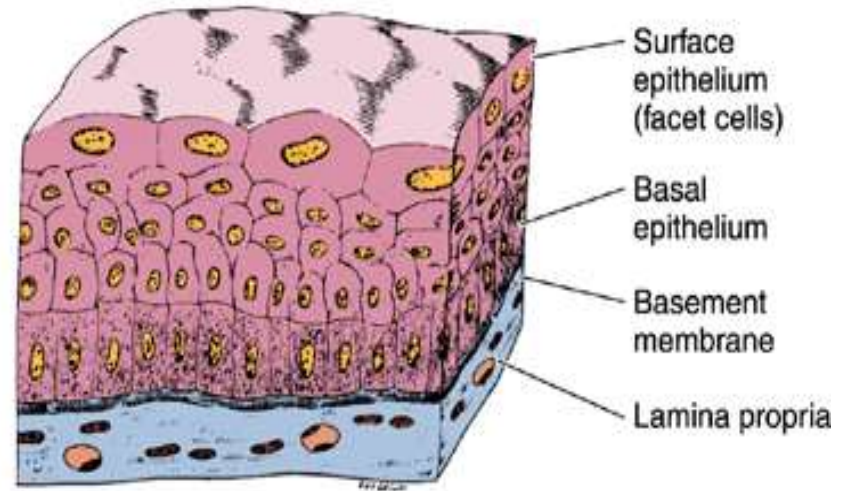
□ **Stratified squamous epithelium**

- **Stratified squamous epithelia vary in thickness depending on the number of cell layers present.**
- **The deepest cells, which are in contact with the basement membrane, are cuboidal or columnar in shape. This layer is usually named the *basal cell layer*, and the cells are called *basal cells*. Basal cells are mitotically active and replace the cells of the epithelium which are lost by "wear and tear".**
- **The basal cell layer is followed by layers of cells with polyhedral outlines.**
- **Close to the surface of the epithelium, cells become more flattened. At the surface of the epithelium, cells appear like flat scales - similar to the epithelial cells of simple squamous epithelia.**

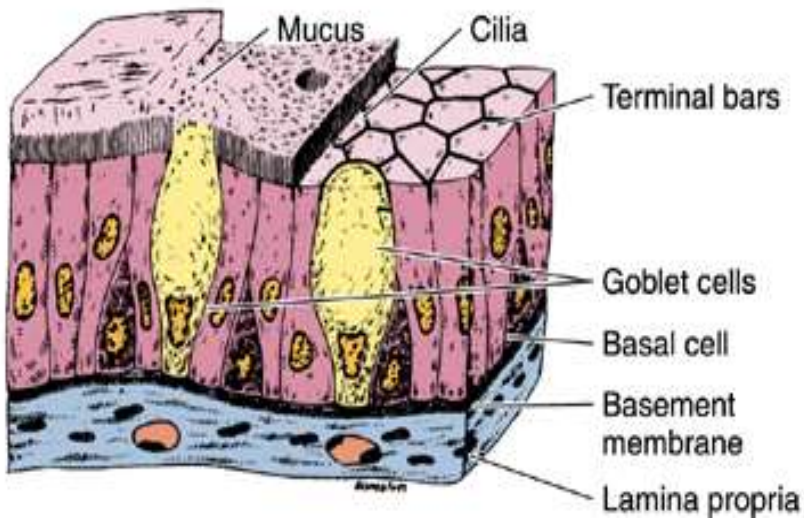
A Stratified squamous epithelium



B Transitional epithelium

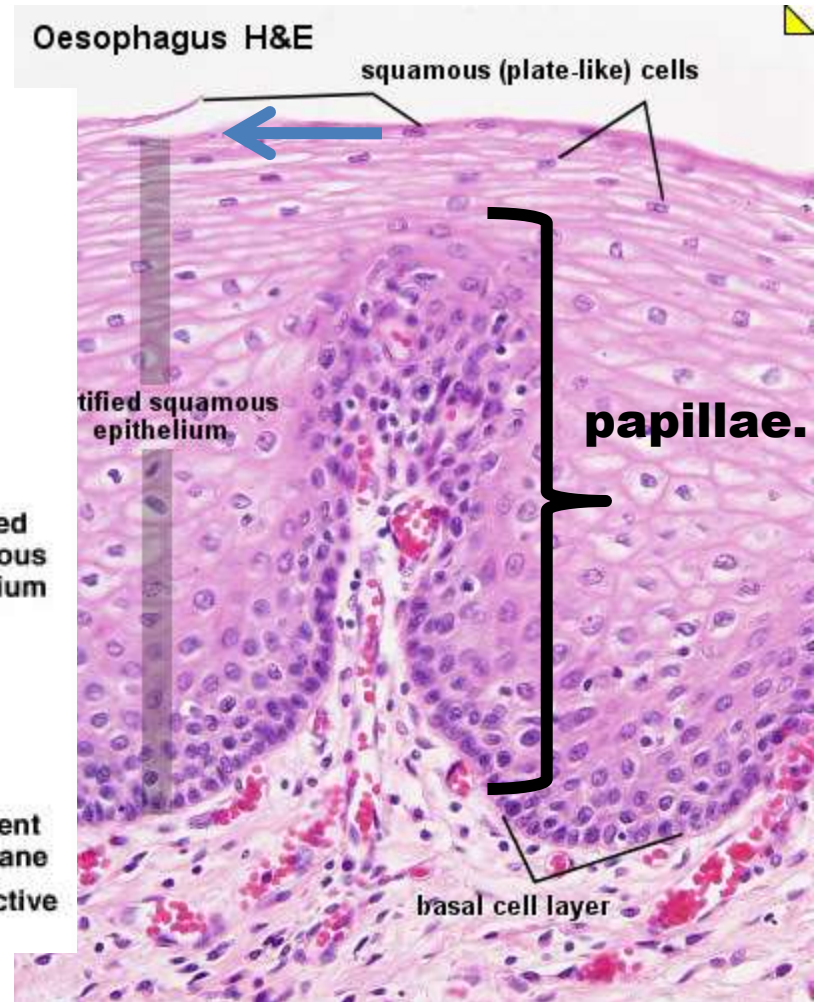
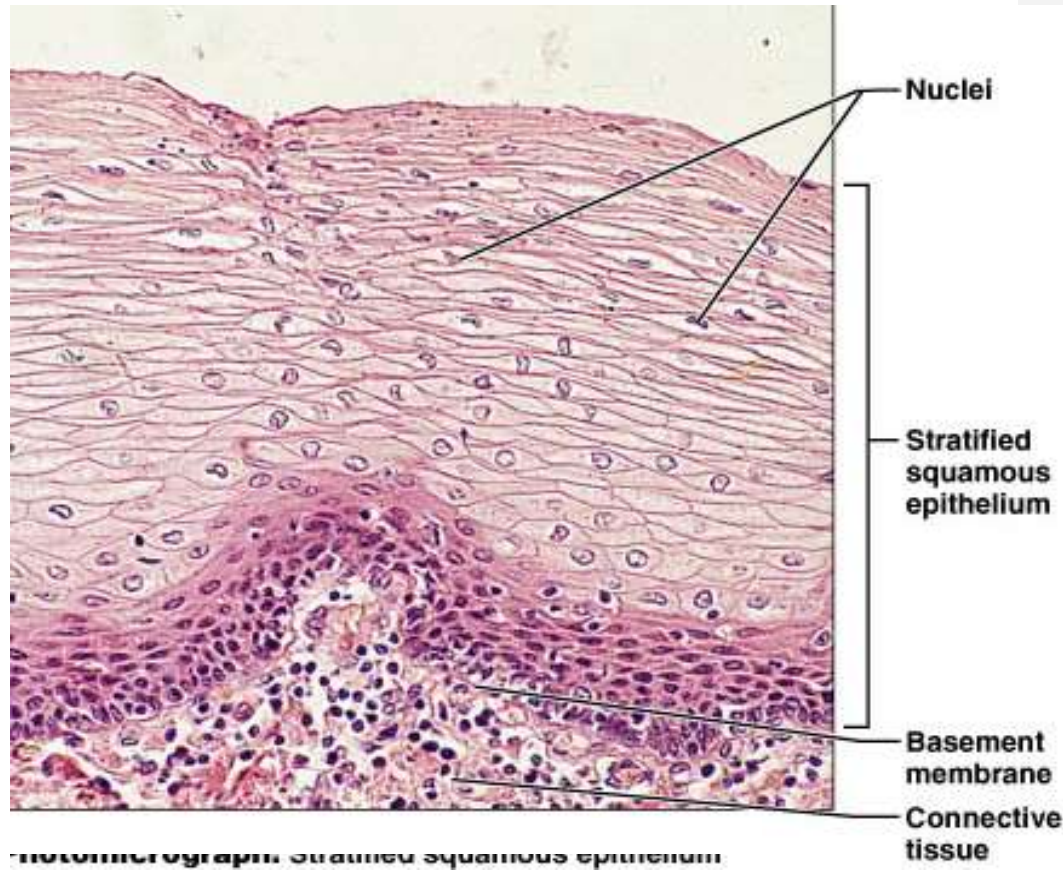


C Ciliated pseudostratified epithelium



❑ **STRATIFIED SQUAMOUS NONKERATINISING EPITHELIUM**

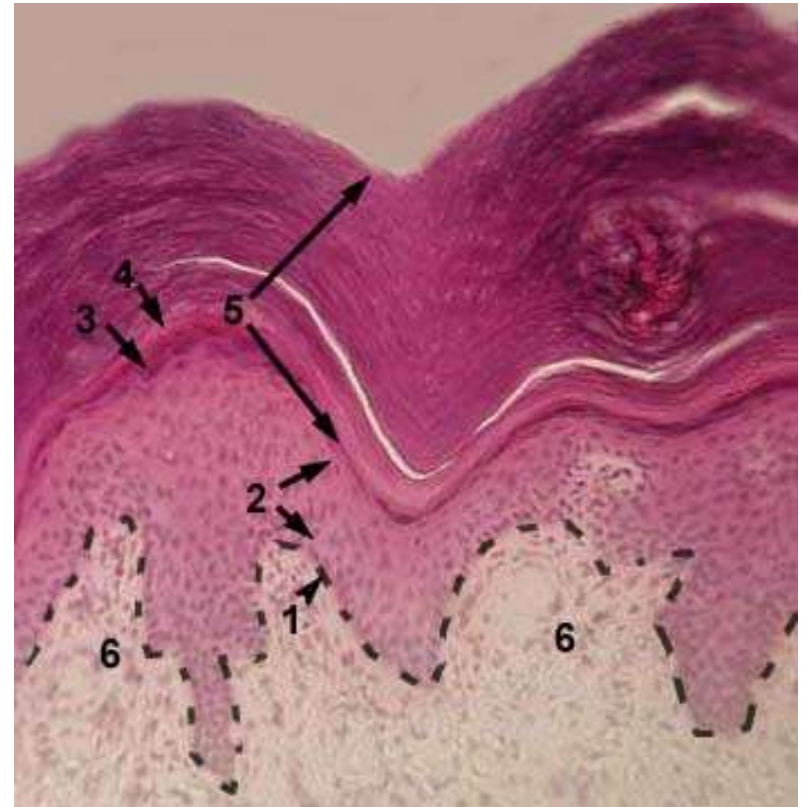
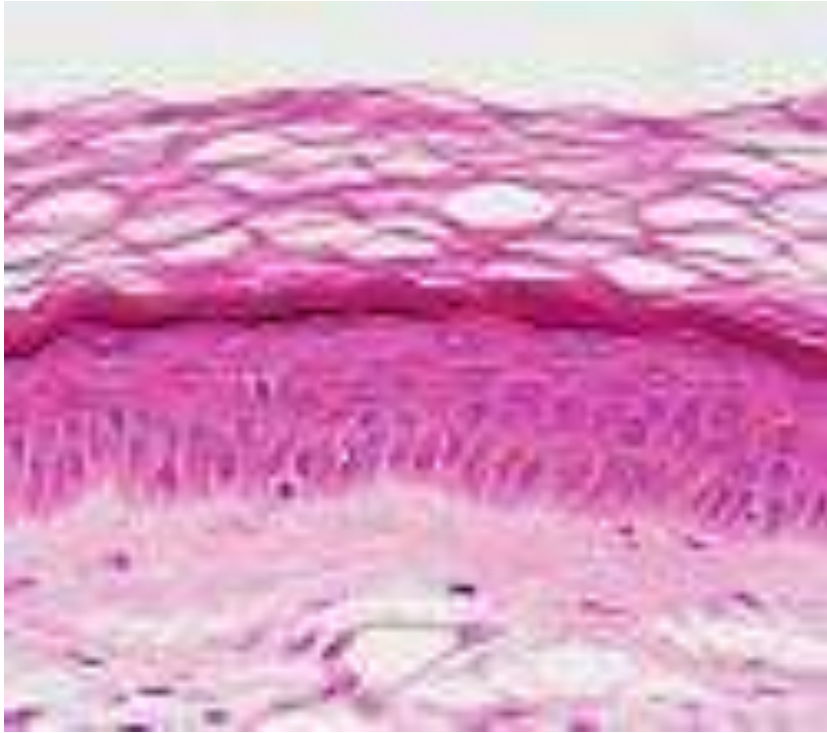- **The oesophagus is lined by a stratified squamous epithelium consisting of many cell layers. Basal cells often form a well defined layer at the border of the epithelium to the underlying connective tissue.**
- **The underlying connective tissue forms finger-like extensions towards the lumen of the oesophagus, which are called papillae.**
- **The border between epithelium and connective tissue may appear quite irregular because of the **papillae**.**
- **This irregular border aids in anchoring of the epithelium to the connective tissue.**



Stratified squamous nonkeratinized (moist) epithelium of the esophagus. The most superficial cells (→ arrow) have the form of very thin scales.

STRATIFIED SQUAMOUS KERATINISING EPITHELIUM

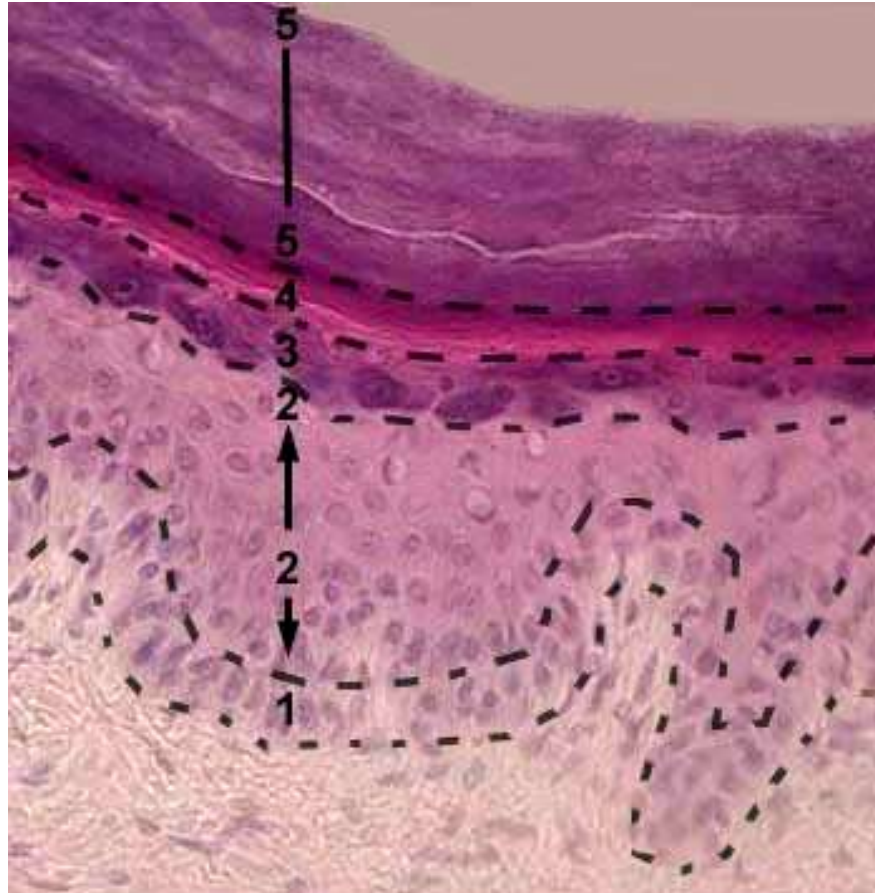**Forming the epithelium of the epidermis of the
Skin.**



STRATIFIED SQUAMOUS KERATINISING EPITHELIUM (EPIDERMIS)

Stained with haematoxylin and eosin.

- 1 - basal layer.**
- 2 - prickle cell layer (stratum spinosum).**
- 3 - granular layer.**
- 4 - lucidar layer.**
- 5 - cornified layer.**



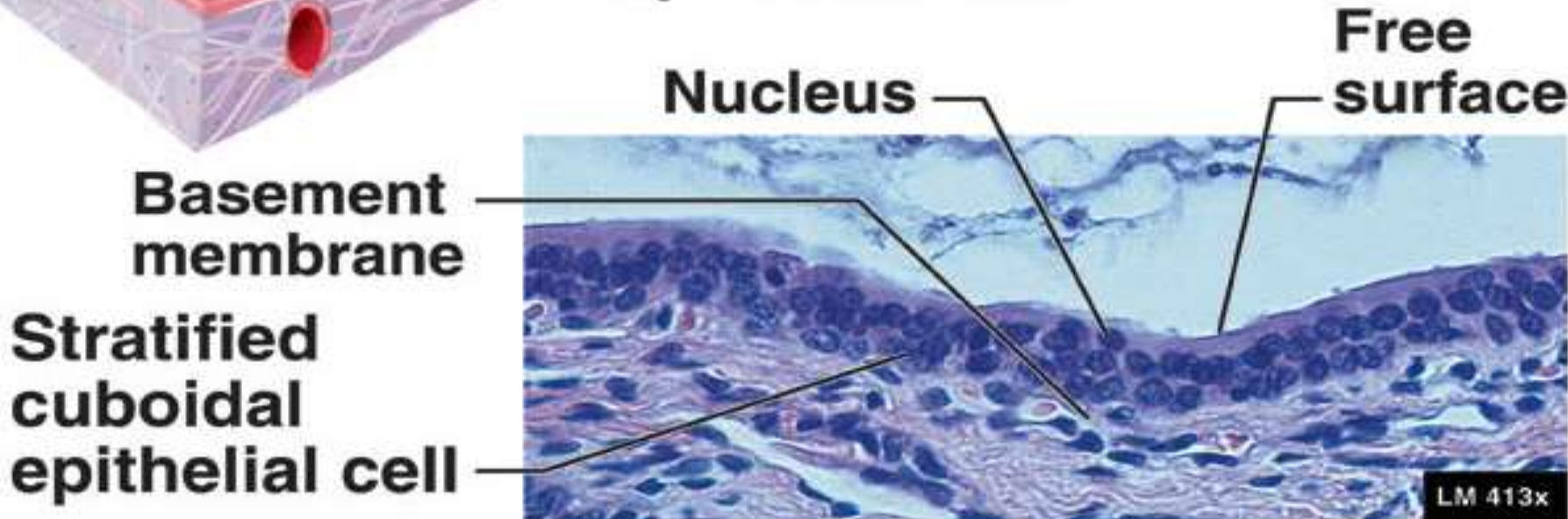
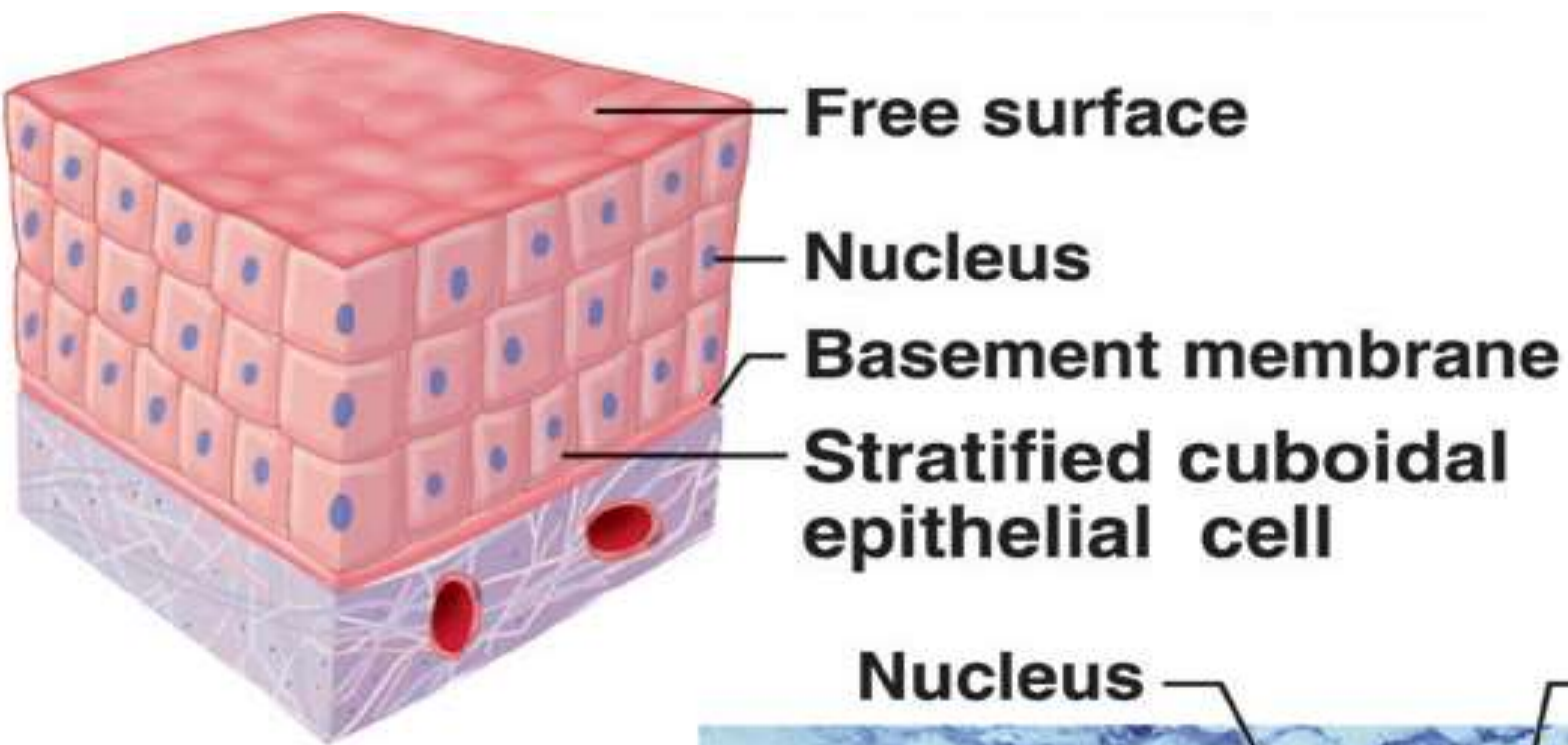
STRATIFIED SQUAMOUS KERATINISING EPITHELIUM (EPIDERMIS)

Stained with haematoxylin and eosin.

- 1 - basal layer.**
- 2 - prickle cell layer (stratum spinosum).**
- 3 - granular layer.**
- 4 - lucid layer.**
- 5 - cornified layer.**

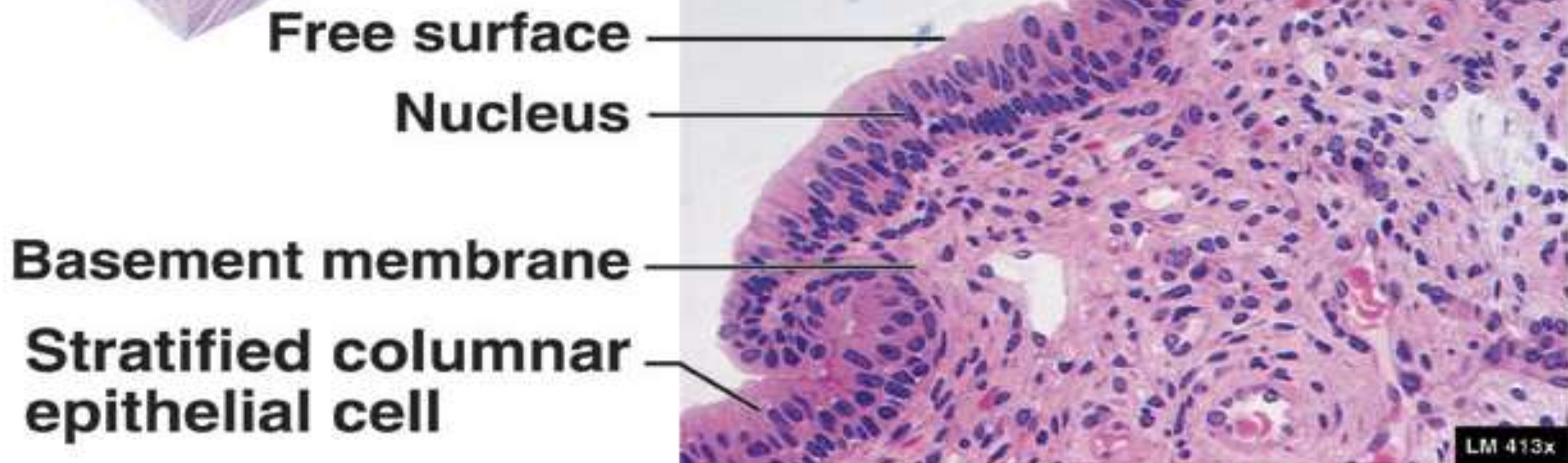
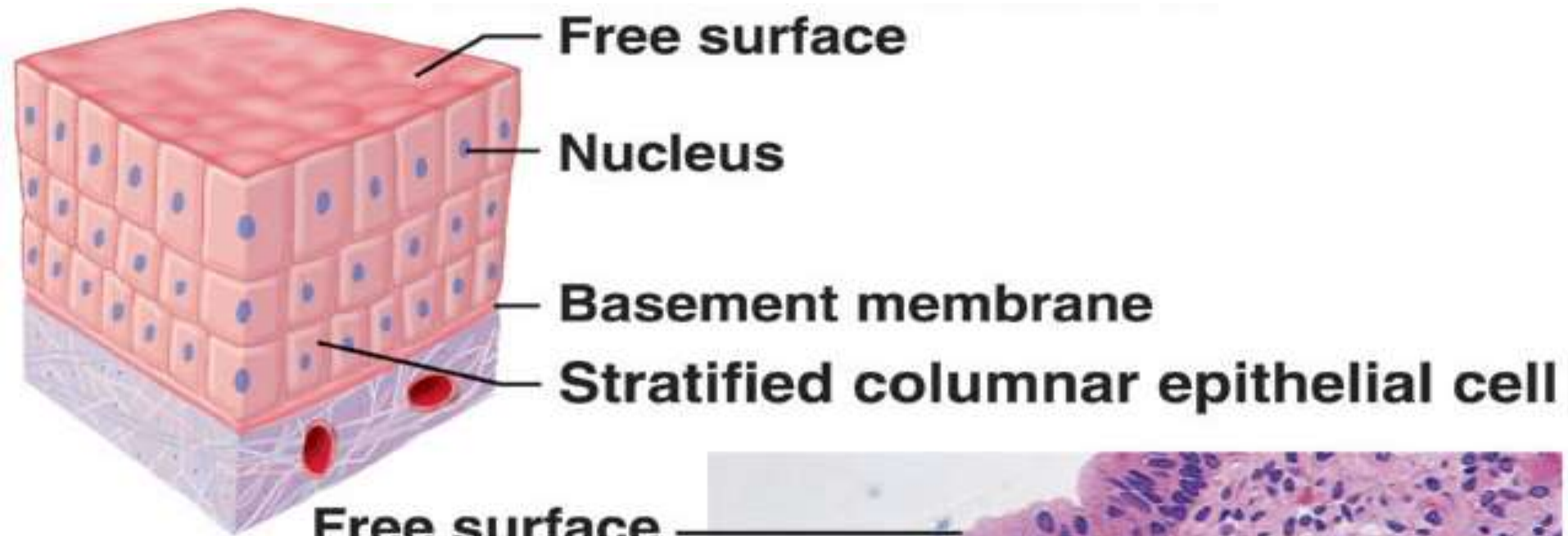Stratified cuboidal and columnar epithelia:

- ❑ **They are not common.**
- ❑ **A two-layered cuboidal epithelium is, for example, seen in the ducts of the sweat glands. Stratified columnar epithelia are found in the excretory ducts of the mammary gland and the main excretory duct of the large salivary glands.**



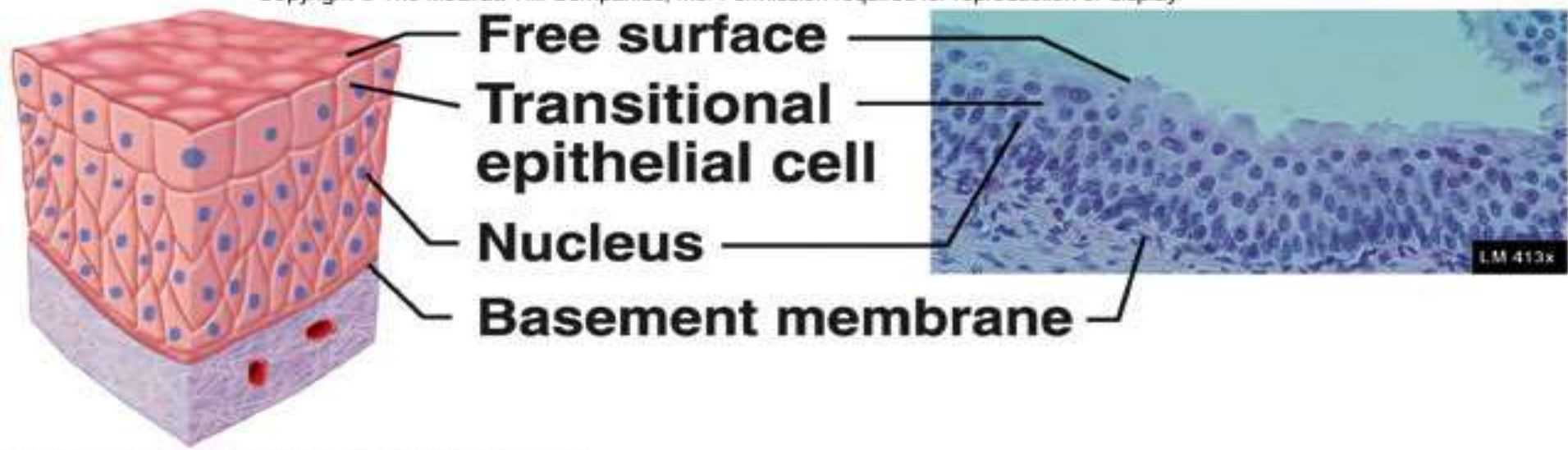
(e) Stratified cuboidal epithelium

Sweat gland ducts, salivary gland ducts, etc.

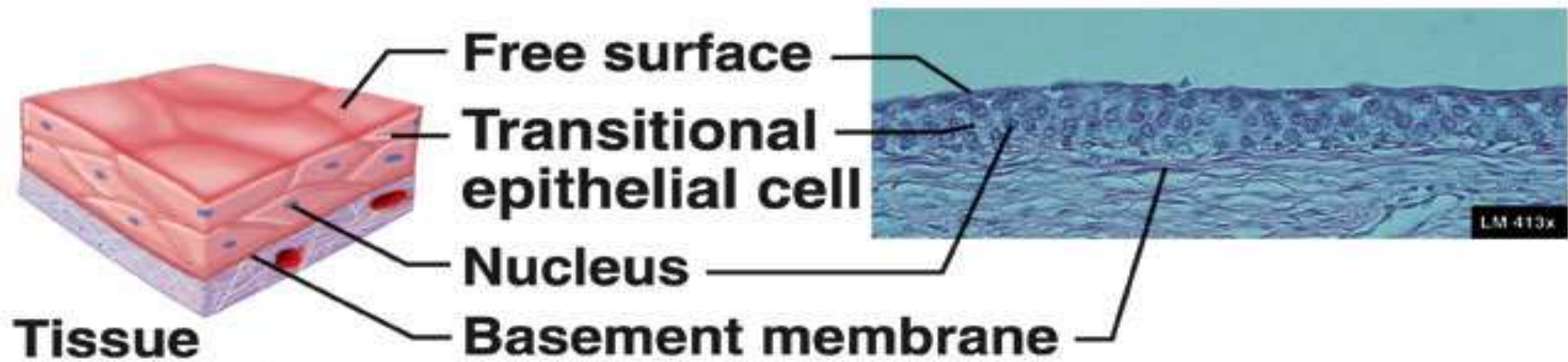


(f) Stratified columnar epithelium

Mammary gland ducts, larynx, urethra (males)



Tissue not stretched



Tissue stretched

(h) Transitional epithelium