

The Nervous System

Lec. 11

L. Hadeel Kamil

Organs and Divisions of the Nervous System

1. Central nervous system (CNS)—brain and spinal cord
2. Peripheral nervous system (PNS)—all nerves
3. Autonomic nervous system (ANS)

Central Nervous System

- Divisions of the brain
 - Brainstem
 - Consists of three parts, named in ascending order: medulla oblongata, pons, and midbrain
 - Structure—white matter with bits of gray matter scattered through it

Central Nervous System

- Diencephalon

- hypothalamus

- Consists mainly of the posterior pituitary gland, pituitary stalk, and gray matter

- thalamus

- Dumbbell-shaped mass of gray matter extending into each cerebral hemisphere

Central Nervous System

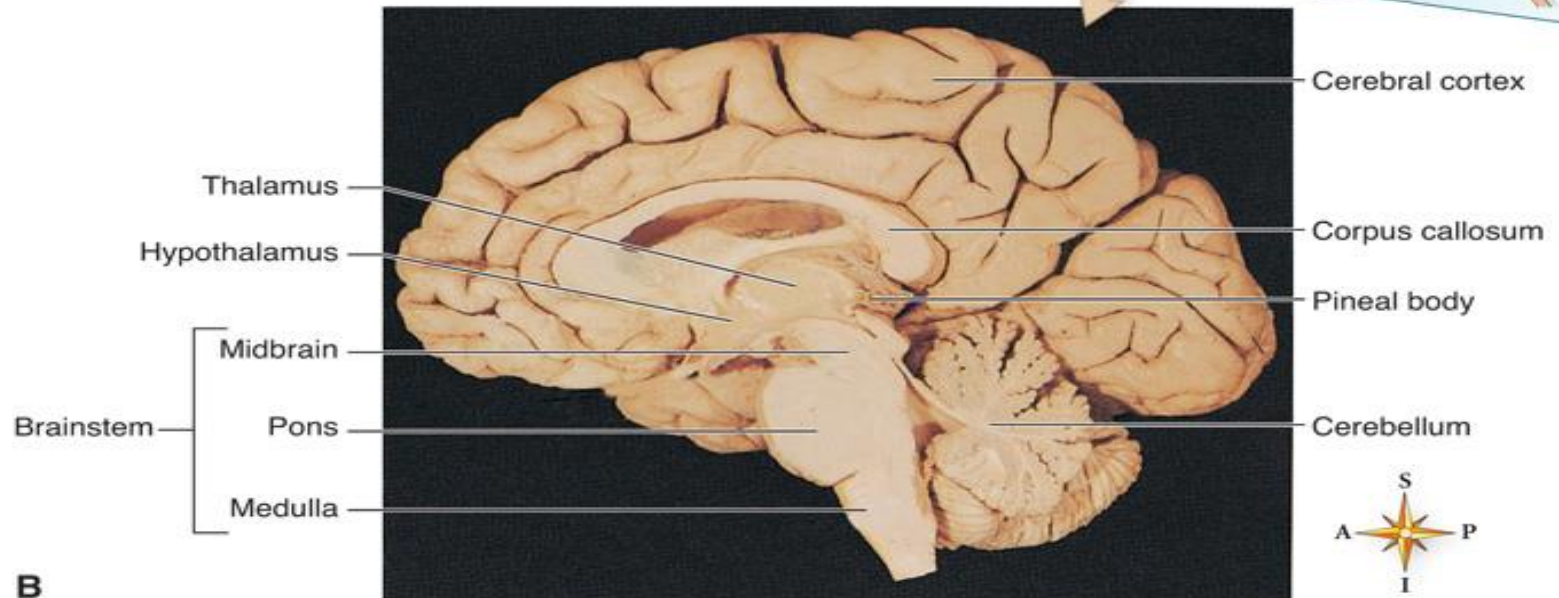
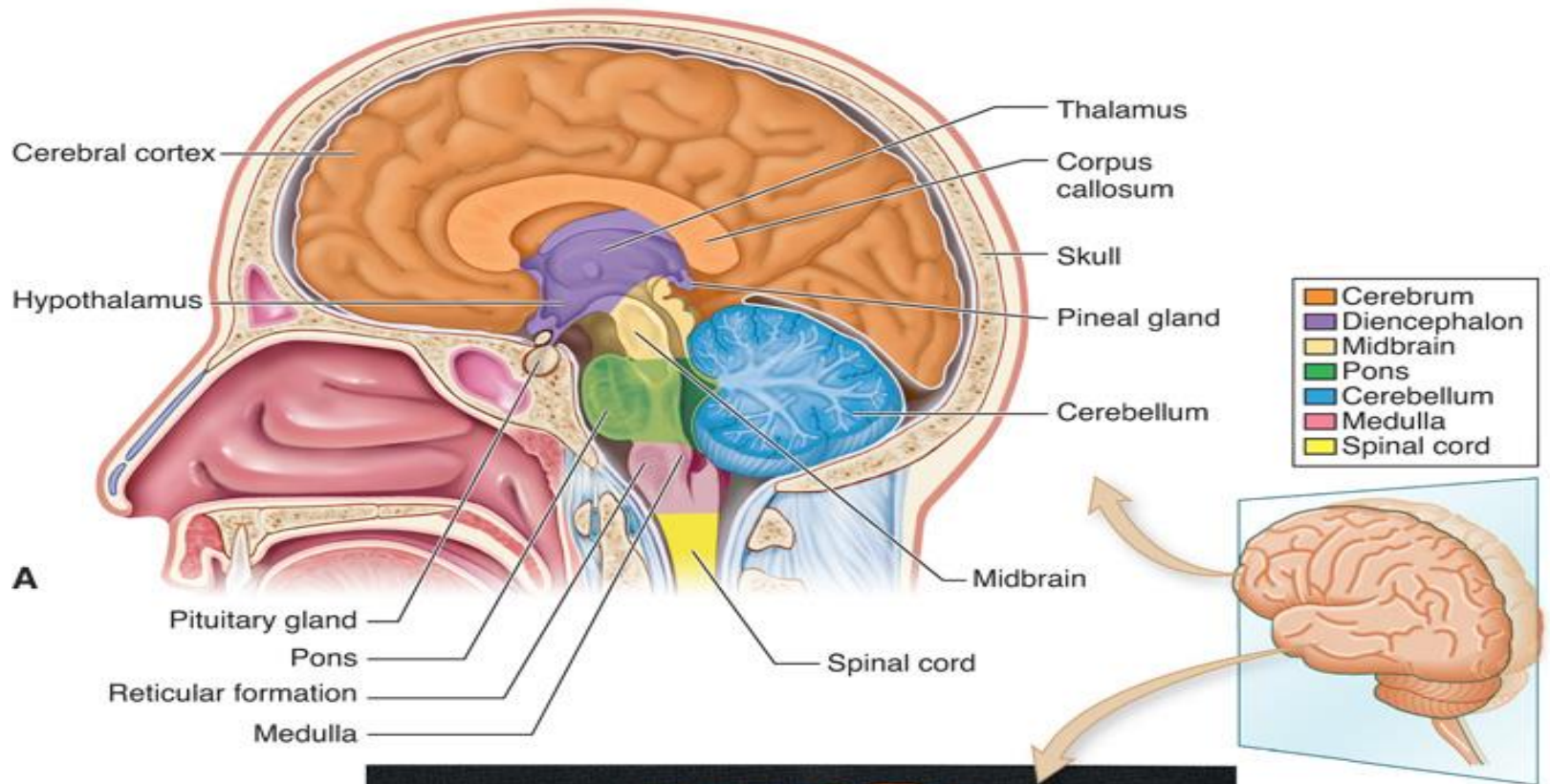
- Cerebellum

- Second largest part of the human brain
- Helps control muscle contractions to produce coordinated movements so that we can maintain balance, move smoothly, and sustain normal postures
- Recent evidence shows the coordinating effects of the cerebellum may be more extensive, also assisting the cerebrum and other regions of the brain

Central Nervous System

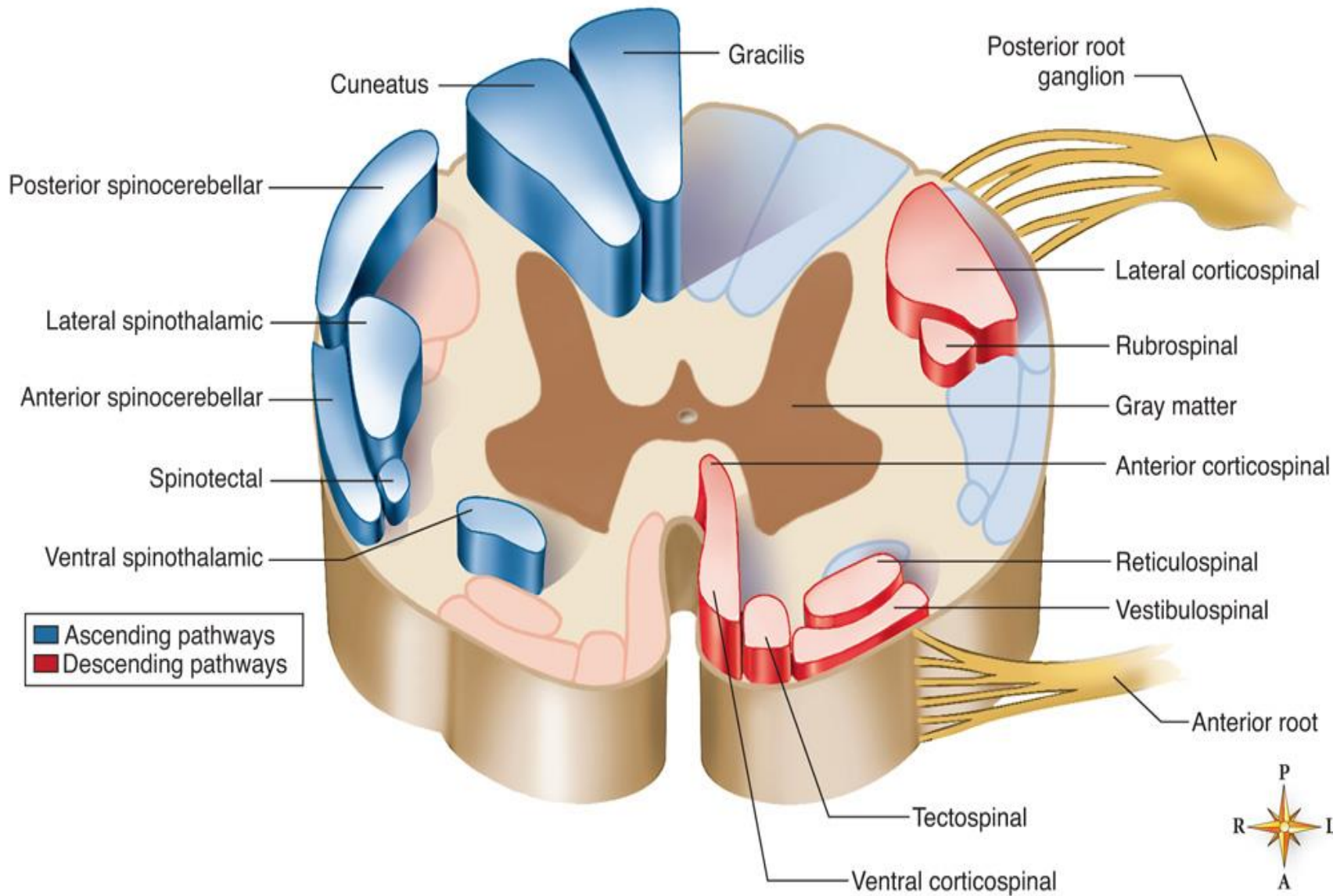
Cerebrum

- Largest part of the human brain
- Outer layer of gray matter is the cerebral cortex; made up of lobes; composed mainly of dendrites and cell bodies of neurons
- Interior of the cerebrum composed mainly of white matter (i.e., nerve fibers arranged in bundles called *tracts*)
- Functions of the cerebrum—mental processes of all types, including sensations, consciousness, memory, and voluntary control of movements



Spinal cord

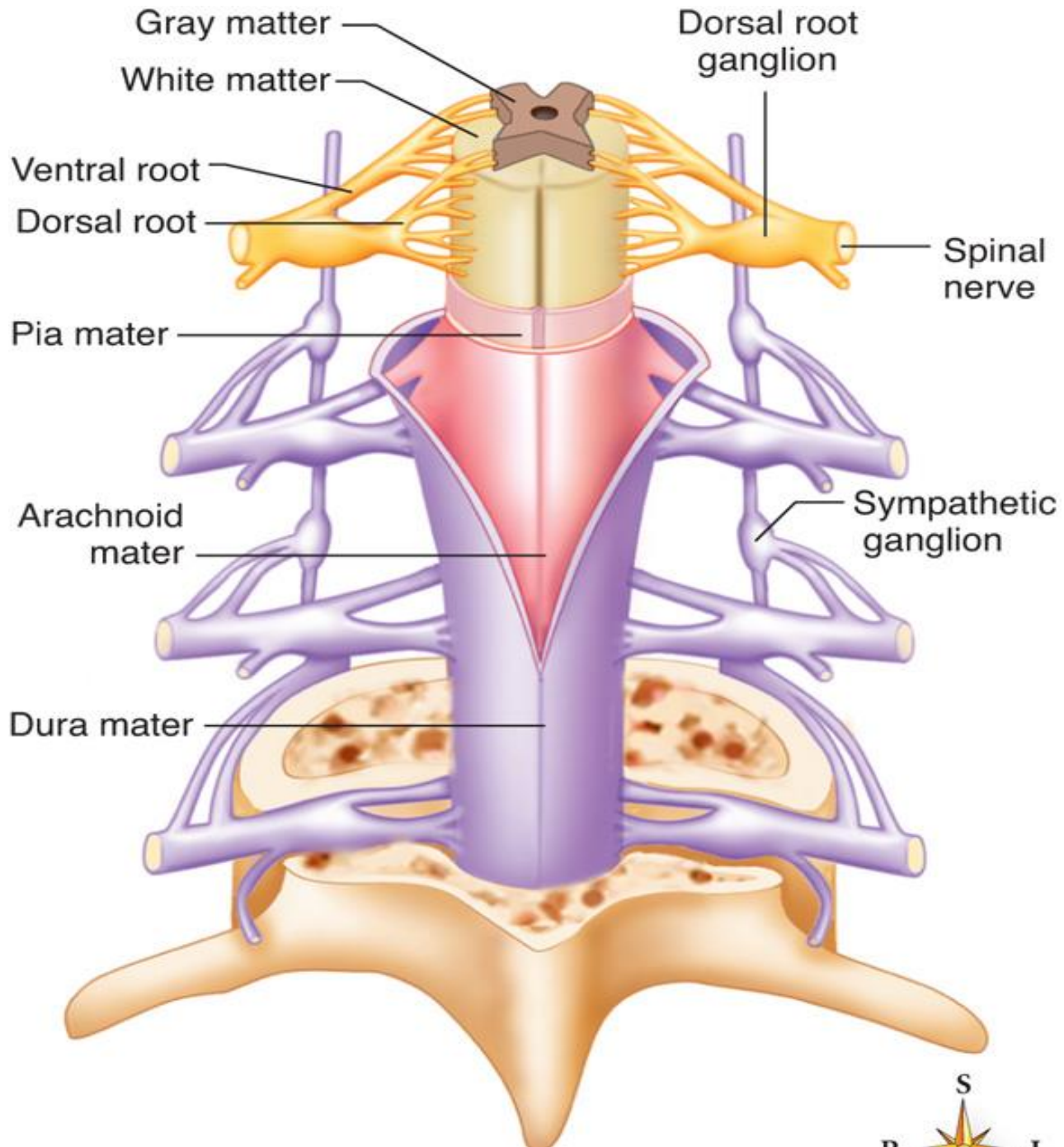
- Columns of white matter, composed of bundles of myelinated nerve fibers, form the outer portion of the H-shaped core of the spinal cord; bundles of axons called *tracts*
- Interior composed of gray matter made up mainly of neuron dendrites and cell bodies
- Spinal cord functions as the primary center for all spinal cord reflexes; sensory tracts conduct impulses to the brain, and motor tracts conduct impulses from the brain

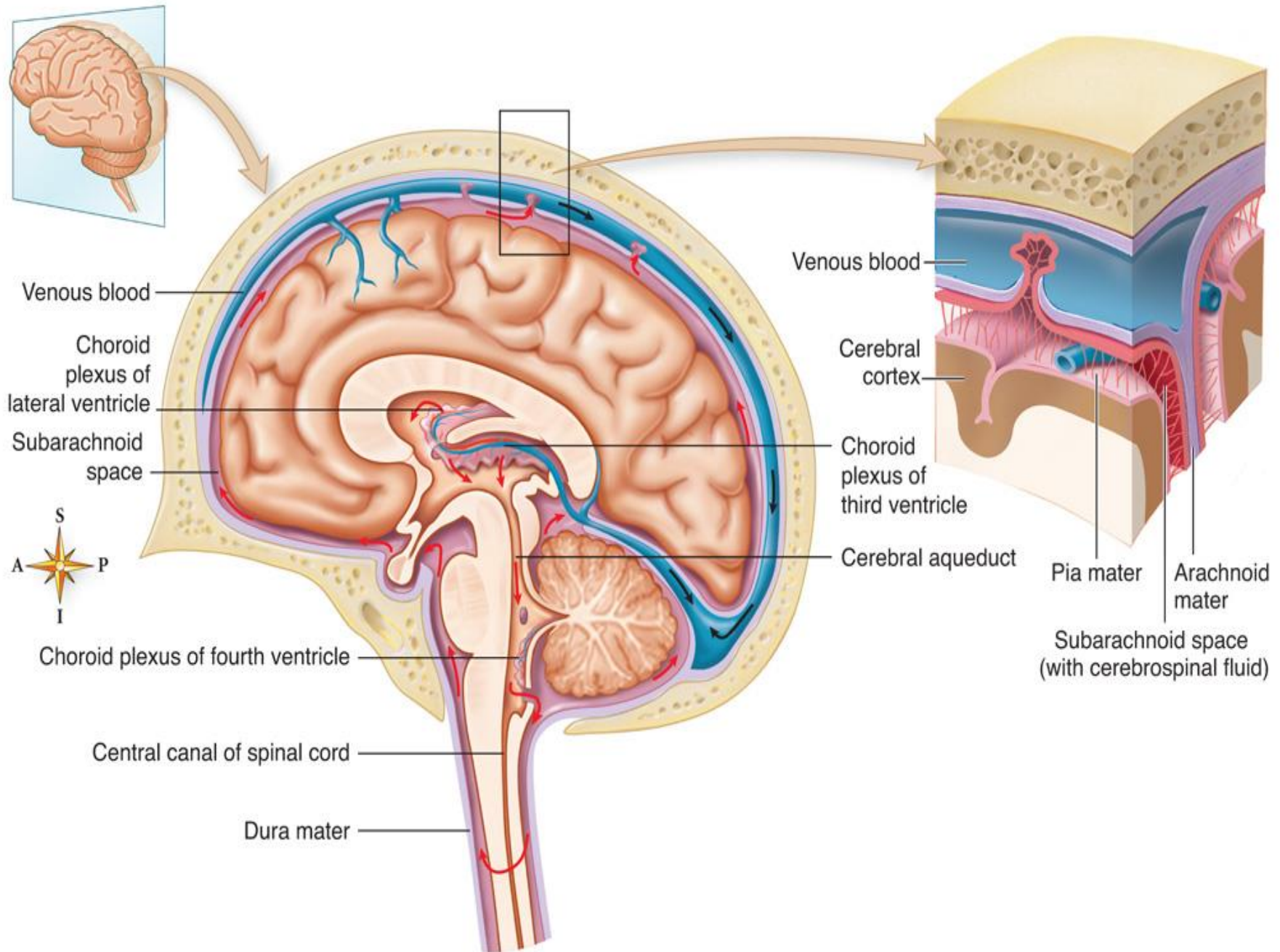


Central Nervous System

Coverings and fluid spaces of the brain and spinal cord

- Coverings
 - Cranial bones and vertebrae
 - Cerebral and spinal meninges—the dura mater, arachnoid mater, and the pia mater
- Fluid spaces
 - Subarachnoid spaces of meninges
 - Central canal inside cord
 - Ventricles in brain





Peripheral Nervous System

Cranial nerves

- 12 pairs—attached to undersurface of the brain
- Connect brain with the neck and structures in the thorax and abdomen

Spinal nerves

- 31 pairs—contain dendrites of sensory neurons and axons of motor neurons
- Conduct impulses necessary for sensations and voluntary movements
- Skin surface area supplied by a single nerve is called a **dermatome**

Autonomic Nervous System

- Autonomic nervous system—motor neurons that conduct impulses from the central nervous system to cardiac muscle, smooth muscle, and glandular epithelial tissue; regulates body's automatic or involuntary functions
- Autonomic neurons—preganglionic autonomic neurons conduct from spinal cord or brainstem to an autonomic ganglion; postganglionic neurons conduct from autonomic ganglia to cardiac muscle, smooth muscle, and glandular epithelial tissue
- Autonomic or visceral effectors—tissues to which autonomic neurons conduct impulses (i.e., cardiac and smooth muscle and glandular epithelial tissue)

Autonomic Nervous System

- Composed of two divisions: the **sympathetic** system and the **parasympathetic system**

1. **Sympathetic nervous system**

- Dendrites and cell bodies of sympathetic preganglionic neurons located in gray matter of thoracic and upper lumbar segments of spinal cord
- Axons leave spinal cord in the anterior roots of spinal nerves, extend to sympathetic or collateral ganglia, and synapse with several postganglionic neurons whose axons extend to spinal or autonomic nerves to terminate in visceral effectors
- A chain of sympathetic ganglia is in front of and at each side of the spinal column

Autonomic Nervous System

- Functions of the sympathetic nervous system
 - Serves as the emergency or stress system, controlling visceral effectors during strenuous exercise and when strong emotions (anger, fear, hate, or anxiety) are elicited
 - Group of changes induced by sympathetic control is called the *fight-or-flight response*

Autonomic Nervous System

- Parasympathetic nervous system
 - Structure
 - Parasympathetic preganglionic neurons have dendrites and cell bodies in the gray matter of the brainstem and the sacral segments of spinal cord
 - Parasympathetic preganglionic neurons terminate in parasympathetic ganglia located in the head and the thoracic and abdominal cavities close to visceral effectors
 - Each parasympathetic preganglionic neuron synapses with postganglionic neurons to only one effector

Autonomic Nervous System

- Parasympathetic nervous system
 - Function—dominates control of many visceral effectors under normal, everyday conditions

Autonomic Nervous System

- Autonomic nervous system as a whole
 - Regulates the body's automatic functions in ways that maintain or quickly restore homeostasis
 - Many visceral effectors are doubly innervated (i.e., they receive fibers from parasympathetic and sympathetic divisions and are influenced in opposite ways by the two divisions)